

G. Olivi, A. Signore, M. Olivi*, M.D. Genovese

University of Genoa, Department of Surgical Science (DISC)

Master Course Laser in Dentistry, Genoa, Italy

*Undergraduated student, Faculty of Dental Medicine

University "Victor Babes", Timisoara, Romania

e-mail: olivi.g@tiscali.it

Lingual Frenectomy: functional evaluation and new therapeutical approach

ABSTRACT

Aim When ankyloglossia is relatively severe and generates mechanical limitations and functional challenges, surgical reduction of the frenum is indicated.

Materials and methods Laser technique is an innovative, safe and effective therapy for frenectomy in both children and adolescents. Erbium:YAG laser (2940nm) can be useful for paediatric dentist: 1.5W at 20pps is a commonly used average power to easily, safely and quickly cut the frenum.

Results Usually after laser frenectomy, the postoperative symptoms and relapse are absent.

Conclusion Early intervention is advisable to reduce the onset of alterations correlated to the ankyloglossia. A multidisciplinary approach to the problem is advisable, in collaboration with orthodontist, physiotherapist and speech therapist, to better resolve the problem.

Keywords Ankyloglossia; Erbium laser; Laser frenectomy; Lingual frenectomy.

Introduction

The lingual frenum is a mucosal fold that connects the bottom of the body of the tongue to the floor of the mouth and to the mandibular bone. When the frenum is thick and very tight and/or its place of insertion limits the mobility of the tongue, it can result in ankyloglossia (from the Greek "ankylos" which means tied and "glossa" which means tongue) [Various authors, 1975].

Ankyloglossia is an embryological anatomical

malformation that usually affects males more than females in a 3:1 ratio. It occurs in newborns with an incidence of about 5%, more frequently as an isolated event and sometimes associated to malformative syndromes (Simpson-Golabi-Behemel Syndrome, Optiz Syndrome, Beckwitz-Wiedemann Syndrome, Oro-facial-digital Syndrome; cleft palate) [Kloars, 2007].

If the anomaly is relatively severe and generates mechanical limitations and functional challenges, surgical reduction of the frenum is indicated, followed by speech therapy for an immediate rehabilitation of the lingual muscle [Campan, 1996].

Furthermore, it should be also emphasised that a short frenum is not always tight or fibrotic; in fact, despite the reduced length of the lingual frenum, the elasticity of the floor of the mouth may still allow a normal mobility of the tongue thus making the frenectomy unnecessary.

Functional problems of ankyloglossia

› Breastfeeding difficulty is caused by the lingual hypomobility and the resulting inability of the nursing infant to squeeze the nipple against the upper arch and hard palate during suction; furthermore, the lateral margins of the tongue raise to form a U-shaped channel that wraps around the nipple to avoid the milk leaking into the vestibule of the mouth. During suction, the lips are also involved as they maintain the nipple in place while providing a seal to prevent loss of milk.

The complexity or, in more severe cases, the inability to correctly perform suction causes weight problems to the infant as well as a decrease in the production of maternal milk during the early stage thus encouraging bottle-feeding [Dollberget al, 2006; Wallace and Clarke, 2006; Srinivasan et al, 2006; Kotlow, 2004; Margolis, 2008].

› Tongue is a fundamental organ for deglutition and a short lingual frenum can become a mechanical impediment to its proper function. Swallowing, a natural function which involves very complex neuromuscular activity, occurs with a progressive push of the tongue apex onto the retroincisal-palatal spot followed by the posterior and medium area of the tongue pressing on the hard palate first and soft palate after, thus ending on the wall of the pharynx. Anyone with ankyloglossia will have difficulty in swallowing, as it will be impossible to perform the movements described above [Garliner, 1996].

› A short and fibrotic lingual frenum can cause functional problems starting at neonatal age with breastfeeding difficulty or early childhood with speech impediment for the correct pronunciation of dento-lingual-labial phonemes due to the reduced lingual mobility. A study on 1402 patients reported that more frequent speech disorders were: omission and substitution of /r/, and consonant clusters with

/r/, and of /s/ and /z/. Frontal and lateral lips also occurred. The relation between altered frenum and speech disorders was considered statistically significant with $p < .001$ [Queiroz Marchesan, 2004].

Orthodontic evaluations

Bearing in mind the close relationship and interdependence between function and form (the "functional matrix" theory of Melvin Moss) [Moss, 1985], we can understand why various orthodontic problems can be correlated with the low position of the tongue and the consequent atypical swallowing [Genovese and Olivi, 2010; García Pola et al, 2002; Defabianis, 2000].

Some of the most frequent problems are:

- › possibility of an anterior and/or posterior cross-bite due to a disproportionate growth of the lower jaw in relation to the upper maxilla. An anomalous and not physiological low lingual posture promotes an excessive growth of the mandible, while the growth of the upper arch is not stimulated in its anterior aspect (premaxilla) and transversal planes by the tongue, during each swallowing process (approximately 1500/2000 times every 24hrs);
- › possibility of an open bite caused by the placement of the tongue in between the two arches during the deglutition and speech;
- › inadequate labial seal and tendency to mouth breathing;
- › possible opening of diastema between the lower incisors resulting from an anomalous lingual thrust.

Postural evaluation

Altered postures are present in individuals with ankyloglossia due to:

- › tongue anatomically attached to the bone and fascial structures of the head and torsum;
- › muscle synergisms existing between the lingual muscle and muscles of the anteromedian chain [Scoppa, 2005];
- › neurophysiological connections between the exteroceptors of the palatine spot (emergency zone of the naso-palatine spot, maxillary nerve ramus which is a branch of the trigeminal nerve), trigeminal nuclei of the encephalic trunk, reticular substance, locus coeruleus, cerebral and cerebellar cortex [Halata and Baumann, 1999; Martin et al, 2004].

Ankyloglossia is normally associated with a higher and more advanced position of the hyoid bone; this condition is the result of the hypertone of the extrinsic and suprahyoid lingual muscles (attached to the jaw and skull) and the consequent stretch of the subhyoid muscles (connected with sternum, clavicle, scapula, larynx, pericardium and mediastinum through the cervical mid-fascia).

Observing the patient from a lateral view:

- 1) The subject may appear with a body posture leaning anteriorly with head and shoulders projected forward and body's center of mass shifted forward. (Fig. 1).

In an attempt to compensate and maintain the body's center of mass over its base of support, and depending on the muscle support, a cervical hyperlordosis (increased cervical lordosis) with high dorsal kyphosis (dorsal kyphosis) (Fig. 2) or a lumbar hyperlordosis (increased dorsal lordosis) with predisposition to abdominal ptosis and inguinal hernia may occur (Fig. 3).

- 2) The subject may appear with a scapular plane in line with the glutei plane (normal scapulium) but with the head propelled forward and straightening of the cervical area; in these subjects, during the dysfunctional deglutition, the head typically performs a "chicken-like" movement [Scoppa, 2005] (Fig. 4, 5).

Tongue assessment

The frenectomy or frenotomy is a surgical procedure

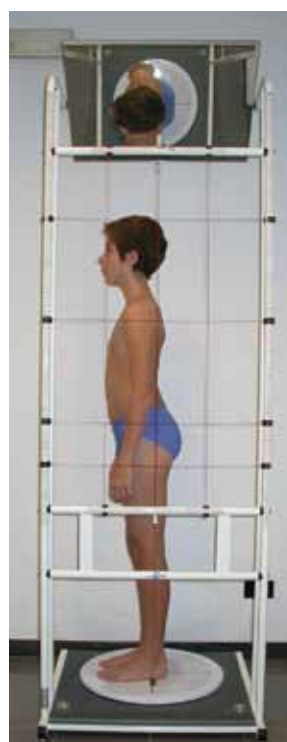

FIG. 1 Postural examination in lateral view: body posture leaning anteriorly with head and shoulders projected forward in relation to the buttocks (front scapulium) and body barycenter moved forward.

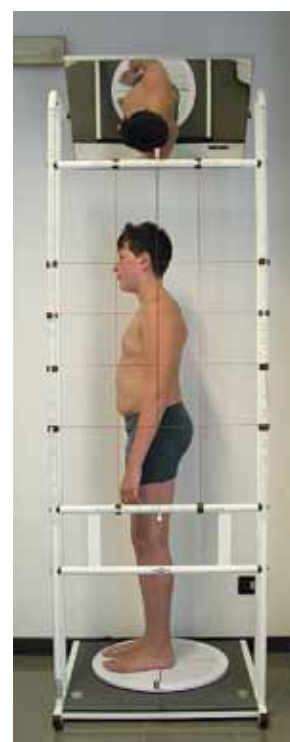

FIG. 2 Postural examination in lateral view: cervical hyperlordosis (increased cervical lordosis) with high dorsal kyphosis (dorsal kyphosis).

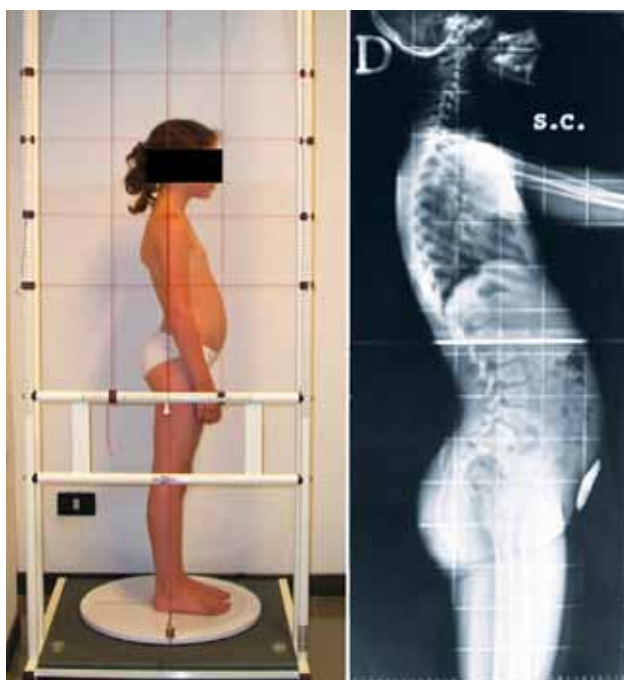


FIG. 3 Postural examination in lateral view: lumbar hyperlordosis (increased dorsal lordosis) with a predisposition to abdominal ptosis and inguinal hernia may increase.

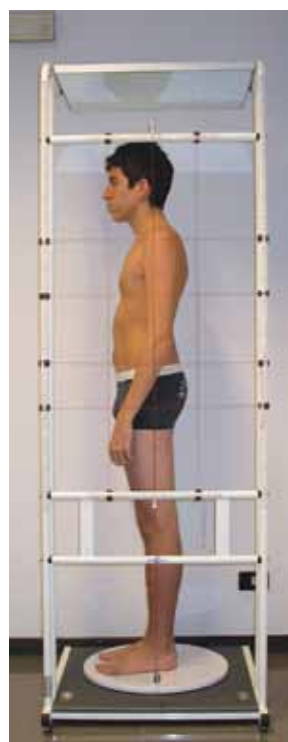

FIG. 4 Postural examination in lateral view: scapular plane in line with the gluteal plane (normal scapulum) but with the head propelled forward and straightening of the cervical area.

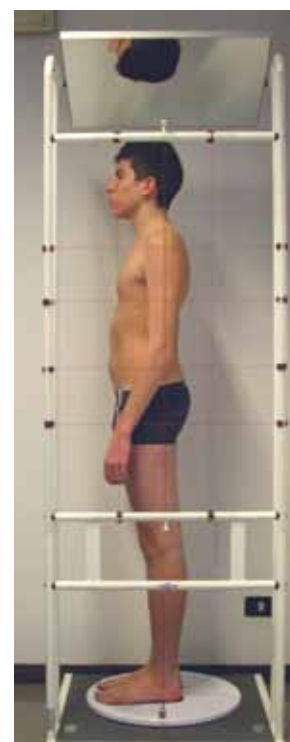

FIG. 5 Postural examination in lateral view: correction of the head and neck position 4 months after lingual frenectomy.

indicated for cases of ankyloglossia with functional impediment.

Surgical intervention must be planned early to avoid functional, anatomical and postural consequences, depending on the severity of the case.

Morphological and functional criteria and tables are available to assist the operator in confirming the indication for surgery:

- › the morpho-functional assessment proposed by Hazelbaker [1993], endorsed by the American Academy of Pediatrics, evaluates the degree of ankyloglossia through a score and the ankyloglossia status is diagnosed with a morphological score less than 8 and functional score less than 11;
- › also a morphological classification, based on the distance from the tip of the tongue to the attachment of the frenum, has been suggested by Kotlow [1999] (Table 1).

Kotlow recommends revising the frenum in case of Class IV and Class III ankyloglossia; Class II and Class I ankyloglossia are the most difficult to evaluate and functional criteria of normal range of motion of the tongue can be utilised for surgical indication. Hence, upon completion of the diagnosis, a clinical-functional evaluation for possible surgical indication has been suggested by Olivi et al. [2011] (Table 2).

It should be stated that a short frenum is not always inelastic or fibrotic and, despite the reduced length, it may allow a normal lingual mobility thus not necessitating a reduction intervention; also,

CLINICALLY ACCEPTABLE NORMAL RANGE OF FREE TONGUE: GREATER THAN 16 MM	
Class I	Mild ankyloglossia: 12 to 16 mm and is mild.
Class II	Moderate ankyloglossia: 8 to 11 mm and is moderate.
Class III	Severe ankyloglossia: 3 to 7 mm and is severe.
Class IV	Complete ankyloglossia: less than 3 mm

TABLE 1 Morphological classification of ankyloglossia (Kotlow L., 1999).

the elasticity of the floor of the mouth can mitigate the effects of the ankyloglossia and help the lingual mobility.

Surgical technique

Traditional frenectomy technique is performed using local anaesthesia, scalpels for incisions according to the technique and sutures. All this requires surgical dexterity as well as the capacity to work with small

Breastfeeding difficulty
Speech impediment
Atypical swallowing
Impossibility to sweep upper and /or lower lips
Limitation of the tongue to reach the palatal retroincisal spot when the mouth is wide open.
Shape of the tongue distorted and/or Invagination at the tongue tip during the protrusion outside the mouth

TABLE 2 Clinical and Functional criteria for surgical indication (Genovese and Olivi, 2011).

patients: often paediatric dentists or oral surgeons do not have both these capabilities.

Laser technique is an excellent alternative to traditional surgery. It is simple and rapid to perform, well accepted and tolerated by patients [Boj et al., 2005; Haytac and Ozcelik, 2006; Genovese and Olivi, 2008; Kara, 2008], requires a minimal anaesthesia, with an asymptomatic postoperative period, without relapse.

Different wavelengths can be utilised for this procedure and the principal concept to remember for all wavelengths is that the minimum effective energy must be used because the lower the energy applied, the less the damage on the targeted tissue and the faster the healing process.

All the wavelengths in the electromagnetic spectrum are useful tools for mucogingival surgery; the visible and non-visible near infrared lasers work in a non-specific mode on the vascular component of the frenum that are not directly responsible for the process of ankylosis, while the medium and far infrared lasers targeting the aqueous component (Hydroxyl radical) of the collagen fibrotic tissue of the frenum are more specific for this procedure.

The KTP (532 nm) laser, the diode laser (810 - 980 nm) and the Nd:YAG laser [Fornaini et al., 2007] can be safely used, allowing for a good and clean cut while also better controlling the bleeding; it is important not to exceed with the frenectomy incision, as this will avoid overtreatment and subsequent fibrotic scars. Special attention should be paid to the parameters used and the exposure time, keeping in mind the different penetration depth of these wavelengths.

The medium and far infrared lasers are the best choice for targeting the fibrotic tissue of the frenum, as they in fact work, superficially, on the aqueous component of collagen fibers.

The CO₂ laser has a distinct affinity for water as well as for collagen (peak of absorption in the 7000 nm) [Bullock, 1995; Fiorotti et al., 2004]. In our clinical practice, according to Kotlow [2004] and Margolis [2008], for this surgical procedure we prefer the Erbium-family laser (2780 nm and 2940 nm).

Materials and methods

Laser surgical intervention may be performed with topical anaesthesia, but we recommend that inexperienced operators use a minimal amount of anaesthetic injected directly and gently in the frenum; 1/3 of vial (about 0.6 ml), using a 30 G needle, is enough to carry out the procedure with minimum stress for both patient and operator.

The use of magnification loupes is advisable; lingual anatomy, the veins and ducts of the salivary glands must be investigated first, with a close-up picture: after this, it will be much easier to select the area of incision and selectively act on the fibrotic component thus avoiding vascular trauma. With this approach, a profuse bleeding will be avoided and the subsequent scar (which is to be avoided) will also be minimised. The tongue is held upwards with a gauze or, better, with a special tongue retractor (W. Lorenz instruments; Miltex GmbH Germany). In this study an Erbium:YAG laser of 2940 nm was used (LightWalker AT-Fotona; Ljubljana Slovenia). Usually, conical tips of different lengths are used: these tips have a smaller terminal diameter which allows for a higher power density (up to 600 micron) (Fig. 6). The incision of the frenum is performed with low-energy (50-60 mJ) and low-frequency pulse (10-15 pps) for a better and easier control in the selective vaporisation of the collagen fibers; pulse frequency can be increased up to 30 pps with power never greater than 1.5-1.8 W, in order to increase the coagulating effect. In the presence of a very fibrotic frenum the energy can be increased up to 75mJ (at 20pps), while maintaining the power at 1.5W.

If the laser pulse duration is adjustable, it is possible to use from 300 microsecond or longer pulse duration (600 microseconds) in order to achieve a better thermal interaction with the tissue. The tissue shows a linear

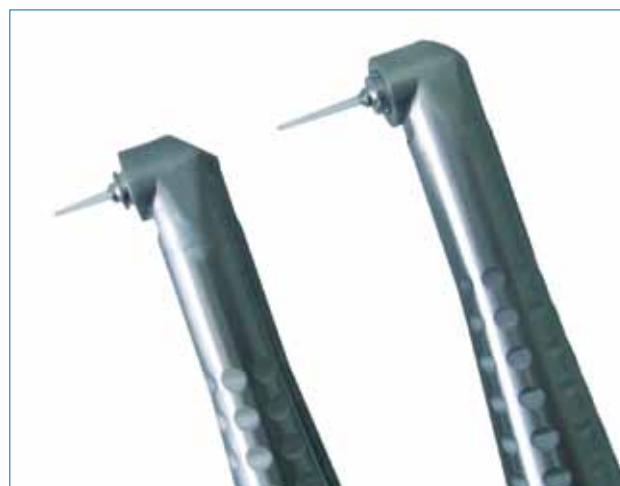

FIG. 6 Erbium laser handpieces with 600 micron conical tips of different length.

temperature rise with increasing duration of irradiation and the effects of laser irradiation vary depending on the level of temperature rise within the target tissue; accordingly surgical intervention is performed with a little air-water spray to cool the tissue as well as keep the targeted area clean and more visible, so that the minimal increase of heat will not produce carbonisation and will allow a healing process with less connective tissue. In order to reduce scar tissue on the frenum, the tongue must be mobilised immediately after the laser session by explaining and instructing the patient to perform simple mobilisation and stretching exercises several times a day; a speech therapy session will start the day after the laser treatment and possible osteopathic care will complete the functional rehabilitation of the lingual fascia [Ferrante, 2004].

Discussion

Early diagnosis and intervention in ankyloglossia are fundamental for the subsequent morpho-functional development of the child and of the adolescent. In the newborn period, the presence of ankyloglossia, with or without a concomitant short upper labial frenum, can already create breastfeeding difficulties. The permanence of atypical swallowing may then be responsible for functional alterations with speech impediment, as well as morphological dentoskeletal alterations with orthodontic problems. The persistence

of these morpho-functional alterations can cause suprahyoid and subhyoid muscular-facial alterations, alterations of the neck muscles and spinal column with a tendency toward altered posture initially and later with postural alteration.

Collaboration with the speech therapist, the physiotherapist/osteopath is fundamental to complete the therapeutic approach.

Laser technology allows early intervention by the paediatric dentist, with a simple and effective laser therapy, eliminating the need to refer the patient to a specialised surgeon for a conventional procedure, thus offering the patient a complete treatment, from diagnosis to minimally invasive therapy. Laser treatment, widely known and documented today, is extremely effective for this type of surgical interventions: it is simple and rapid to perform for the clinician and is safe and minimally invasive for the patient. Laser therapy is always better accepted than traditional therapy; the post-operative period is usually asymptomatic; relapse is minimal or absent (fig. 7).

The use of the Erbium:YAG laser is particularly effective. It is selective for hydroxyl radical fibrotic tissue; if utilised with water spray, there is no thermal damage, minimizing scar tissue and post-operative pain. The laser procedure does not require sutures, eliminating a technical step that is often difficult in the child and decreasing operating time; a second intention healing allows the tissue to heal with an increase in tissue formation.

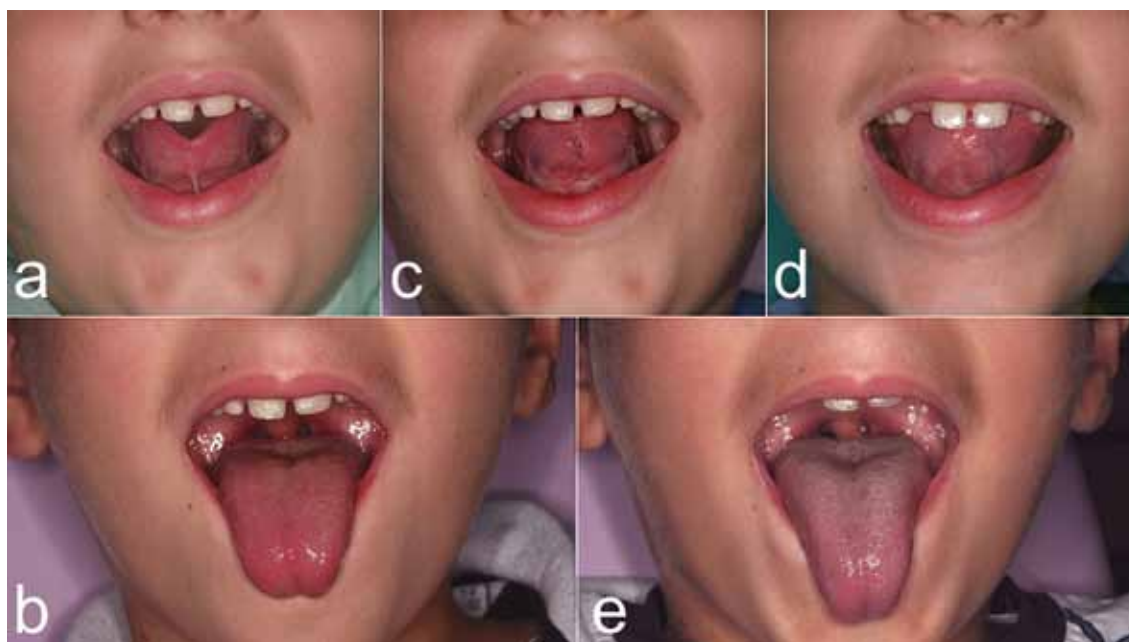


FIG. 7 Short lingual frenum: a) shape of the tongue distorted (cleft); short distance from the tip of the tongue to the attachment of the frenum; b) functional reduction of lingual movement: limitation of the tongue to reach the palatal retroincisal spot when the mouth is wide open; c) Erbium laser frenectomy at 1,4W, 20pps and 70mJ. Water 3-Air 2. Selective and minimally invasive incision of the lingual frenum with no bleeding; d,e) healing and improved lingual function after 3 weeks.

Moreover the laser is seen by the patient and parents as a less invasive and magical instrument and, for this reason, better tolerated and accepted.

Conclusion

Early diagnosis of ankyloglossia is important for correct morpho-functional growth in the child. The use of laser therapy is always more diffused as a valid and effective instrument in infantile orthodontics. The lingual frenectomy procedure with the Erbium:YAG laser has been demonstrated to be simple and safe. A multidisciplinary approach completes the therapy and improves the results. It is important to underline that a period of education in laser physics and training is highly recommended before applying this technology on paediatric patients. However, correct information and motivation of both parents and children as well as an adequate psychological approach to the patient are important elements for the full success of the therapy.

References

- › Boj J, Galofre N, Espana A, Espasa E. Pain perception in paediatric patients undergoing laser treatments. *J Oral Laser Applications* 2005;2:85-89.
- › Bullock N Jr. The use of the CO₂ laser for lingual frenectomy and excisional biopsy. *Compend Contin Educ Dent* 1995;16(11):1118-23.
- › Campan P, Baron P, Duran D, Casteigt J. Lingual frenectomy: a therapeutic protocol. A technic for frenectomy with 2 incision lines combined with active postoperative kinesitherapy during and after healing. *Schweiz Monatsschr Zahnmed* 1996;106(1):45-54.
- › Defabianis P. Ankyloglossia and its influence on maxillary and mandibular development. (A seven year follow-up case report). *Funct Orthod* 2000;17(4):25-33.
- › Dollberg S, Botzer E, Gunis F, Mimouni FB. Immediate nipple pain relief after frenotomy in breast-fed infants with ankyloglossia: a randomized, prospective study. *J Pediatr Surg* 2006; 41(9):1598-600.
- › Ferrante A. *Manuale pratico di terapia miofunzionale*. Roma: Marrapese Editore 2004.
- › Fiorotti RC, Bertolini MM, Nicola JH, Nicola EM. Early lingual frenectomy assisted by CO₂ laser helps prevention and treatment of functional alterations caused by ankyloglossia. *Int J Orofacial Myology* 2004;30:64-71.
- › Fornaini C, Rocca JP, Bertrand MF, Merigo E, Nammour S, Vescovi P. Nd:YAG and diode laser in the surgical management of soft tissues related to orthodontic treatment. *Photomed Laser Surg* 2007;25(5):381-92.
- › García Pola MJ, González García M, García Martín JM, Gallas M, Seoane Lestón J. A study of pathology associated with short lingual frenum ASSDC *J Dent Child* 2002;69(1):59-62.
- › Garliner D. *Importanza di una corretta deglutizione*. Acquaviva Picena (AP): Futura Publishing Society; 1996.
- › Genovese MD, Olivi G. Laser in paediatric dentistry: patient acceptance of hard and soft tissue therapy. *Eur J Paediatr Dent* 2008;9(1):13-7.
- › Genovese MD, Olivi G. Use of laser technology in Orthodontics: hard and soft tissue laser treatments. *Eur J Paediatr Dent* 2010;11(1):44-8.
- › Halata Z, Baumann KL. Sensory nerve endings in the hard palate and papilla incisiva of the rhesus monkey. *Anat Embryol (Berl)* 1999; 199:427-37.
- › Haytac M.C, Ozcelik O. Evaluation of patient perceptions after frenectomy operations: a comparison of carbon dioxide laser and scalpel techniques. *J Periodontol* 2006;77(11):1815-9.
- › Hazelbaker AK. *The Assessment Tool for Lingual Frenulum Function: Use in a Lactation Consultant Private Practice*. (Master's Thesis), 1993. Self-Published by A.B.R.E.A.S.T. center for breastfeeding.
- › Kara C. Evaluation of Patient Perceptions of Frenectomy: A Comparison of Nd:YAG Laser and Conventional Techniques. *Photomed Laser Surg* 2008 Mar 16 [Epub ahead of print].
- › Kloars T. Familial ankyloglossia (tongue tie). *Int J Pediatr Otorhinolaryng* 2007;71:1321-24.
- › Kotlow LA. Ankyloglossia (tongue-tie): a diagnostic and treatment quandary. *Quintessence Int* 1999;30(4):259-62.
- › Kotlow LA. Oral diagnosis of oral frenum attachments in neonates and infants: evaluation and treatment of the maxillary and lingual frenum using the Erbium:YAG laser. *Journal Pediatric Dental Care* 2004;10(3): 11-13.
- › Margolis F. Erbium:YAG Lasers Infant Frenectomies. *Dentalcompare* 2008;12.
- › Martin RE, Macintosh BJ, Smith RC, Barr AM, Stevens TK, Gati JS, Menon RS. Cerebral areas processing swallowing and tongue movement are overlapping but distinct: a functional magnetic resonance imaging study. *J Neurophysiol* 2004 ;92:2428-2443.
- › Moss M. Hipótesi de la matrice funzionale. *Dent Clinic North Am* 1985;14(3).
- › Olivi G, Margolis F, Genovese MD. *Pediatric Laser Dentistry: a User's guide*. Quintessence Publishing Co, Inc; 2011. p162-175.
- › Queiroz Marchesan I. Lingual frenulum: classification and speech interference. *Int J Orofacial Myology* 2004; 30:31-8.
- › Scoppa F. Gosso postural syndrome. *Annali Stomatologia* 2005;54(1): 27-34.
- › Srinivasan A, Dobrich C, Mitnik H, Feldman P. Ankyloglossia in breastfeeding infants: the effect of frenectomy on maternal nipple pain and lactch. *Breastfeed Med* 2006;1(4):216-24.
- › Various authors. *Anatomia Umana*. Milano: ed.Ermes; 1975. vol.I-III.
- › Wallace H, Clarke S. Tongue tie division in infants with breast feeding difficulties. *Int J Pediatr Otorhinolaryngol* 2006;70(7):1257-61.