

# Obstructive Sleep Apnea: Brain Structural Changes and Neurocognitive Function before and after Treatment

Nicola Canessa<sup>1,2,3,4\*</sup>, Vincenza Castronovo<sup>5\*</sup>, Stefano F. Cappa<sup>1,2,3,4</sup>, Mark S. Aloia<sup>6</sup>, Sara Marelli<sup>5</sup>, Andrea Falini<sup>3,7</sup>, Federica Alemanno<sup>1,3,4</sup>, and Luigi Ferini-Strambi<sup>4,5</sup>

<sup>1</sup>Center for Cognitive Neuroscience, and <sup>2</sup>CRESA, Vita-Salute San Raffaele University, Milan, Italy; <sup>3</sup>CERMAC, <sup>5</sup>Sleep Disorders Center, and <sup>7</sup>Neuroradiology Unit, Vita-Salute San Raffaele University and San Raffaele Scientific Institute, Milan, Italy; <sup>4</sup>Division of Neuroscience, San Raffaele Scientific Institute, Milan, Italy; and <sup>6</sup>Department of Medicine, National Jewish Medical and Research Center, Denver, Colorado

**Rationale:** Obstructive sleep apnea (OSA) is commonly associated with neurocognitive impairments that have not been consistently related to specific brain structure abnormalities. Knowledge of the brain structures involved in OSA and the corresponding functional implications could provide clues to the pathogenesis of cognitive impairment and its reversibility in this disorder.

**Objectives:** To investigate the cognitive deficits and the corresponding brain morphology changes in OSA, and the modifications after treatment, using combined neuropsychologic testing and voxel-based morphometry.

**Methods:** A total of 17 patients treatment-naïve to sleep apnea and 15 age-matched healthy control subjects underwent a sleep study, cognitive tests, and magnetic resonance imaging. After 3 months of treatment, cognitive and imaging data were collected to assess therapy efficacy.

**Measurements and Main Results:** Neuropsychologic results in pre-treatment OSA showed impairments in most cognitive areas, and in mood and sleepiness. These impairments were associated with focal reductions of gray-matter volume in the left hippocampus (entorhinal cortex), left posterior parietal cortex, and right superior frontal gyrus. After treatment, we observed significant improvements involving memory, attention, and executive-functioning that paralleled gray-matter volume increases in hippocampal and frontal structures.

**Conclusions:** The cognitive and structural deficits in OSA may be secondary to sleep deprivation and repetitive nocturnal intermittent hypoxemia. These negative effects may be recovered by consistent and thorough treatment. Our findings highlight the importance of early diagnosis and successful treatment of this disorder.

**Keywords:** obstructive sleep apnea; brain structure; neurocognitive function; treatment

Obstructive sleep apnea (OSA) is a common sleep disorder, affecting at least 2 to 4% of middle-aged individuals. OSA is associated with neurocognitive and cardiovascular morbidities (1), reduced quality of life (2), impaired work performance, and increased risk of vehicular and industrial accidents (3).

Patients with OSA demonstrate several neuropsychologic impairments (4, 5), but the link between these deficits and localized brain dysfunction is debated (6–8). Repeated apneic

## AT A GLANCE COMMENTARY

### Scientific Knowledge on the Subject

The article assesses the effect of obstructive sleep apnea on brain structure and cognitive performance, and the changes after treatment with continuous positive airway pressure.

### What This Study Adds to the Field

Cognitive impairment is associated with a decrease of gray-matter volume in specific cerebral regions. This can be reversed by treatment with an increase of gray-matter volume in specific hippocampal and frontal brain regions. These changes are significantly correlated with improvement in specific neuropsychologic tests (executive functioning and short-term memory), underlining the importance of early diagnosis and treatment of sleep apnea.

and hypopneic events during sleep result in intermittent hypoxemia, hypercapnia, cortical and sympathetic nervous system arousal, and sleep fragmentation (6, 9). Intermittent hypoxemia is associated with increased sympathetic vasoconstriction and decreased vascular protective mechanisms, which can contribute to structural and functional changes in the vasculature of the brain (4, 7, 9).

Neuroimaging studies may aid in identifying patients at greatest risk for poor outcome by examining relationships between brain integrity and functional response to treatment. The available structural imaging studies are largely inconsistent because of methodologic and sample variability (7, 8). Results of structural studies investigating gray-matter (GM) density or volume changes are also heterogeneous, although hippocampal involvement is reported frequently (10–14).

Voxel-based morphometry (VBM) (15, 16) studies have demonstrated a GM-density reduction in frontal, parietal, temporal, hippocampal, and cerebellar regions of patients with OSA (10). Similarly, Yaouhi and coworkers (12) reported GM loss in frontal and temporo-parieto-occipital cortices and hippocampal and cerebellar regions despite minor memory and motor impairments. Only hippocampal and parahippocampal GM loss was observed by other investigators (11). O'Donoghue and coworkers (17) found GM-density loss in the posterior hippocampal cortex and the left insular region before treatment only with an uncorrected statistical threshold, and no region showing a significant GM increase after treatment using a corrected threshold. They suggested that the variability in results across studies was related to VBM methods and statistical threshold settings.

We hypothesized that neuropsychologic changes in patients with OSA may be associated with localized brain changes, and

(Received in original form May 4, 2010; accepted in final form October 28, 2010)

\* These authors contributed equally to this work.

Supported by Respiration Foundation, Pittsburgh, Pennsylvania.

Correspondence and requests for reprints should be addressed to Vincenza Castronovo, Ph.D., Sleep Disorders Center, Vita-Salute San Raffaele University and San Raffaele Scientific Institute, Milan, Via Stamira d'Ancona 20, 20127, Italy. E-mail: castronovo.vincenza@hsr.it

This article has an online supplement, which is accessible from this issue's table of contents at [www.atsjournals.org](http://www.atsjournals.org)

Am J Respir Crit Care Med Vol 183, pp 1419–1426, 2011

Originally Published in Press as DOI: 10.1164/rccm.201005-0693OC on October 29, 2010  
Internet address: [www.atsjournals.org](http://www.atsjournals.org)

that these changes may be at least partially reversed by effective treatment. We tested the hypotheses that structural brain differences would exist between patients with OSA and control subjects, and in patients with OSA before and after 3 months of treatment. Preliminary results of this study have been previously reported in the form of an abstract (18).

## METHODS

### Participants

Seventeen severe treatment-naive male patients with OSA (age range, 30–55) and 15 male age- and education-matched healthy control subjects were studied. Inclusion criteria for OSA were apnea-hypopnea index (AHI) greater than 30. Inclusion criteria for control subjects were AHI less than five and free of psychiatric and medical disorders. Exclusion criteria were symptoms of cognitive deterioration (Mini-Mental <24); sleep disorders other than OSA; hypertension (>160/100); diabetes; use of psychoactive medications; and structural brain abnormalities (additional details are provided in the online supplement). There was no significant demographic difference between patients and control subjects (Table 1). Participants provided written informed consent to the experimental procedure, which was approved by the local Ethical Committee of Vita-Salute San Raffaele University, Milan, Italy. Participants were evaluated at baseline and after 3 months of treatment with continuous positive airway pressure (CPAP) (with C-flex, M-series; Phillips/Respironics, Murraysville, PA). One OSA participant dropped out because of low adherence to CPAP treatment. Full nocturnal polysomnography was performed at baseline and after treatment. Apnea events were defined as any 80% drop of respiratory amplitude lasting more than 10 seconds; hypopneas were defined as any 30% drop of respiratory amplitude lasting more than 10 seconds associated with greater than 3% desaturation, or with arousal (19). AHI was calculated as an index of the number of apnea and hypopnea events per hour of sleep. All participants underwent magnetic resonance imaging 2 to 3 hours after waking the morning after the sleep study.

### Neuropsychologic Evaluation

All participants underwent a neuropsychologic evaluation (20) of short- and long-term memory, executive functions, constructional abilities, vigilance, attention, and abstract reasoning (*see online supplement*). In addition, participants completed the self-report Epworth Sleepiness Scale to evaluate daytime somnolence, the Beck Depression Inventory to evaluate mood, and SF-36 to assess overall quality of life. Tests were administered in Italian and scored according to the published

procedures (20). Group differences were investigated using nonparametric two-sample (Mann-Whitney U test) and paired (Wilcoxon signed-rank test) *t* tests.

### Magnetic Resonance Imaging Data Acquisition

T1-weighted magnetic resonance images were acquired with a 3-T Philips Achieva scanner (Best, The Netherlands).

### VBM Data Preprocessing and Statistical Analysis

Image preprocessing and statistical analyses were performed using SPM5 (<http://www.fil.ion.ucl.ac.uk/spm>) on Matlab v7.4 (Mathworks, Inc., Sherborn, MA), and the VBM5.1-toolbox (<http://dbm.neuro.uni-jena.de>) (*see online supplement*).

Focal GM-volume differences between pretreatment OSA and control subjects, and between pretreatment and post-treatment OSA, were investigated using two-sample and paired *t* tests, respectively, with age as nuisance variable. Unless otherwise stated, the statistical threshold was *P* less than 0.05, family-wise error corrected at the cluster level (21) (primary threshold at the voxel level of *P* < 0.005 uncorrected). In a separate analysis we replicated the methods of O'Donoghue and coworkers (17) to compare our results directly with their negative data.

Cerebral regions showing significant effects were identified using the cytoarchitectonic-mapping implemented in the SPM Anatomy Toolbox (22).

Regions of interest analyses with the SPM5 toolboxes Marsbar (<http://marsbar.sourceforge.net/>) and Anatomy Toolbox (22) highlighted group differences in GM volume, and correlations between the latter, disease severity (AHI and hypoxia) and performance in neurocognitive tests showing a significant behavioral effect, in both the clusters resulting from VBM analyses and cytoarchitectonic (anatomically independent) subdivisions of the hippocampus (23). Here the threshold was *P* less than 0.05 corrected for multiple comparisons using false-discovery rate.

## RESULTS

### Neurocognitive Data

Before treatment patients and control subjects were similar on demographic measures, whereas they differed significantly in body mass index and sleepiness (OSA participants were higher than control subjects) (Table 1), and on all neurocognitive measures (patients with OSA were poorer than control subjects)

TABLE 1. DEMOGRAPHIC AND CLINICAL DATA

	Baseline			Follow-up	
	Controls ( <i>n</i> = 15)	OSA ( <i>n</i> = 17)	<i>P</i> Value	OSA ( <i>n</i> = 16)*	<i>P</i> Value
Demographic data					
Age, yrs	42.15 (6.64)	44 (7.63)	ns	43.37 (7.41)	ns
Education, yrs	13.23 (3.09)	12.24 (2.70)	ns	12.31 (2.77)	ns
Clinical data					
Body mass index, kg/m <sup>2</sup>	26.10 (2.50)	31.24 (4.35)	0.01	31.09 (4.45)	ns
Apnea-hypopnea index	1.6 (1.5)	55.83 (19.08)	0.001	2.5 (2.4)	0.001
Mean SaO <sub>2</sub> , %	93.1 (1.5)	70.41 (9.13)	0.012	91.4 (1.9)	0.016
Time SaO <sub>2</sub> below 90%, min	0.3 (1.2)	30.42 (13.4)	0.001	0.8 (0.5)	0.001
CPAP use, min/night				349.36 (34.15)	
Days of CPAP use >4 h, %				82.5 (9.78)	
Mean CPAP pressure, cm H <sub>2</sub> O				11.5 (2.9)	
Blood pressure, systolic, mm Hg	121.32 (3.99)	123.85 (10.44)	ns	120.89 (9.23)	ns
Blood pressure, diastolic, mm Hg	81.00 (4.31)	83.41 (5.82)	ns	82.69 (6.65)	ns
Beck Depression Inventory	1.46 (2.16)	3.76 (3.94)	0.007	1.75 (2.95)	0.01
Epworth Sleepiness Scale	3 (1.25)	11.94 (5.47)	<0.001	2.81 (2.78)	<0.001
SF36 (quality of life), total score	80.89 (9.37)	68.91 (15.43)	0.01	80.35 (15.09)	0.002

Definition of abbreviations: CPAP = continuous positive airway pressure; ns = nonstatistically significant; OSA = obstructive sleep apnea.

Comparison of demographic and clinical data between control subjects and patients with OSA pretreatment, and between patients with OSA pretreatment and post-treatment.

\* One drop-out for low treatment compliance.

TABLE 2. NEUROPSYCHOLOGIC DATA

Neuropsychologic scores	Baseline			Follow-up	
	Controls (n = 15)	OSA (n = 17)	P Value	OSA (n = 16)*	P Value
Global cognitive functions					
Mini Mental State Evaluation	30.00 (0.00)	29.35 (1.05)	ns	29.75 (0.57)	ns
Raven	34.6 (1.29)	31.70 (3.90)	0.002	33.25 (2.46)	0.03
Short-term memory					
Digit-span forward	6.93 (0.70)	5.58 (1.00)	<0.001	6.56 (0.81)	0.002
Corsi	6.53 (0.91)	5.11 (1.05)	0.001	6.18 (0.83)	0.002
Long-term memory					
Rey-list (learning)	58 (7.01)	48.70 (9.67)	0.006	58.18 (7.92)	<0.001
Rey-list (recall)	13 (1.96)	10.58 (2.47)	0.003	13.12 (2.24)	0.002
Rey-list (recognition)	14.86 (0.51)	14.29 (1.10)	0.03	14.87 (0.34)	0.01
Rey-list (false-positives)	0.13 (0.35)	1 (1.17)	0.02	0.37 (0.61)	ns
Attention and executive functions					
Digit-span backward	5.6 (0.91)	4.17 (1.01)	0.001	5.12 (0.88)	0.004
Stroop (time)	23.06 (8.13)	39.12 (21.88)	0.009	34.73 (17.57)	ns
Stroop (errors)	0.73 (1.03)	5.31 (3.57)	<0.001	0.86 (1.35)	<0.001
Trail-making test (A)	22.73 (5.72)	26.82 (4.50)	0.02	23.18 (7.29)	0.03
Trail-making test (B)	59.4 (14.16)	82.35 (24.19)	0.005	78.87 (21.79)	ns
Paced Auditory Serial Addition Test (errors)	5.13 (3.58)	21.52 (10.07)	<0.001	7.31 (7.17)	<0.001

Definition of abbreviations: ns = non statistically significant; OSA = obstructive sleep apnea.

Comparison of neuropsychologic data between control subjects and patients with OSA pretreatment, and between patients with OSA pretreatment and post-treatment.

\* One drop-out for low treatment compliance.

(Table 2). After treatment patients showed a significant improvement in sleepiness and in all cognitive tests, except for total time on Stroop test (executive functions); false-positives at Rey list recognition (long-term memory); and Trail Making Test B (executive functions). Mood (even if always in normal ranges) and quality of life (SF-36) significantly improved after treatment.

#### Brain Structural Changes before CPAP Treatment

A significant reduction of GM volume in pretreatment patients, compared with control subjects, was observed in the left posterior parietal cortex and right superior frontal gyrus (Figure 1, Table 3; Table E1 in the online supplement). We observed no GM-volume increase in patients compared with control subjects, even when using an uncorrected  $P$  value ( $P < 0.005$ ). Motivated by *a priori* hypotheses of OSA-related hippocampal abnormalities (10–14), we focused on the hippocampus with an uncorrected threshold of  $P$  less than 0.005. We found reduced GM volume in participants with OSA, compared with control subjects, in the left parahippocampal gyrus (entorhinal cortex). In all of these regions, GM volume was negatively correlated with errors at the Stroop test (executive functions). GM volume in the left posterior parietal cortex was also positively correlated with performance in the Raven test (abstract reasoning) and negatively correlated with sleepiness score (Table 4 and Table E2). With regard to disease severity, we observed a significant negative correlation between AHI and time with  $\text{SaO}_2$  less than 90% and GM volume in the left posterior parietal cortex ( $P < 0.05$ ), and a trend toward statistical significance between AHI and GM volume in the right superior frontal gyrus ( $P = 0.067$ ) (Table 5).

Neither overall GM volume nor white matter volume or total intracranial volume significantly differed between pretreatment patients with OSA and control subjects (two-sample  $t$  test, two-tailed,  $P > 0.05$ ), although we observed a trend for reduced GM volume in the former group ( $P = 0.09$ ) (Table E3).

Because patients and control subjects differed significantly in body mass index, specific analyses were run to test for its potential effect on brain structure. No significant correlation between GM volume and body mass index was found (Table E4 and Figure E1).

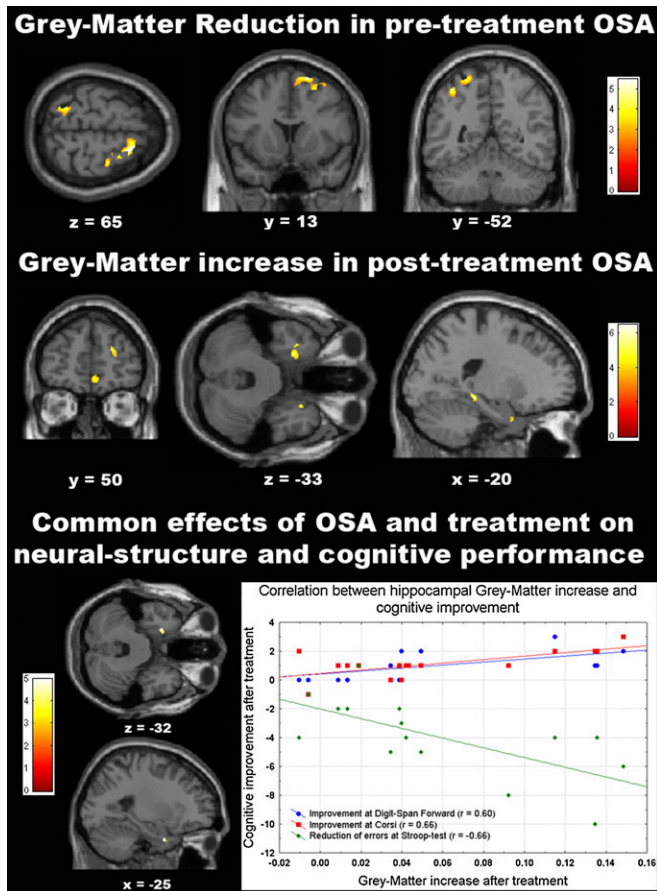
#### Brain Structural Changes after CPAP Treatment

No specific brain region showed a significant GM reduction after treatment, even when using an uncorrected  $P$  value ( $P < 0.005$ ). Instead, specific hippocampal (left subiculum and bilateral entorhinal cortex) and frontal (superior and middle frontal gyri, and medial orbitofrontal cortex) clusters demonstrated a GM-volume increase (Figure 1, Table 3, and Table E1). The GM volume increase in the left hippocampus was correlated with the improvement on the Stroop test (executive function) (Table 4 and Table E2). Among the previously mentioned cerebral regions, OSA severity (AHI and time with  $\text{SaO}_2 < 90\%$  before treatment) was positively correlated with hippocampal GM-volume increase after treatment in the right entorhinal cortex and in the left subiculum ( $P < 0.05$ ) (Table 5). There was also a trend for a positive correlation between AHI and GM volume in the right middle and superior frontal gyrus ( $P = 0.061$ ) and left entorhinal cortex ( $P = 0.052$ ).

After treatment with CPAP a significant increase of overall GM volume was observed in patients with OSA ( $P < 0.05$ ), despite no significant increase of total intracranial volume ( $P > 0.5$ ). Indeed, the average amount of GM-volume increase was associated with a comparable, yet nonstatistically significant ( $P = 0.13$ ), reduction in cerebrospinal fluid volume (Table E3).

#### Hippocampal Structural Changes before and after Treatment (CPAP)

A conjunction analysis (conjunction-null test) (24) revealed brain regions demonstrating group effects both before (OSA vs. control subjects) and after (with-treatment OSA vs. treatment-naive OSA) CPAP treatment. This analysis highlighted the left anterior parahippocampal gyrus (entorhinal cortex) (Figure 1, Table 3, and Table E1), where GM-volume increase after treatment was correlated with improved performance in the Digit-Span Forward (verbal short-term memory), Corsi (visuospatial short-term memory), and Stroop tests (executive functions) (Figure 1, Table 4, and Table E2). In addition, we observed in this region a trend toward a significant positive correlation ( $P = 0.072$ ) between GM volume and level of hypoxia (time with  $\text{SaO}_2 < 90\%$  and nadir  $\text{SaO}_2$ ) (Table 5).



**Figure 1.** Structural brain changes in obstructive sleep apnea (OSA) before and after continuous positive airway pressure treatment. (*Top row*) Regions showing a gray matter (GM) volume decrease in untreated patients with OSA compared with control subjects ( $P < 0.05$  corrected for multiple comparisons based on cluster-extent) (20). (*Middle Row*) Regions showing a GM-volume increase in post-treatment, compared with pretreatment, patients with OSA ( $P < 0.05$  corrected for multiple comparisons based on cluster-extent) (20). (*Bottom Row*) Left hippocampal entorhinal cortex showing both a GM-volume reduction before treatment and a GM-volume increase after treatment ( $P < 0.001$  uncorrected for multiple comparisons based *a priori* hypotheses) (10–14), and the correlation between GM-volume increase in this region and cognitive improvement after treatment ( $P < 0.05$  corrected for multiple comparisons with false-discovery rate). Significant clusters are projected on representative slices of a brain template in stereotaxic space. The distance (in millimeters) of each slice from the anterior commissure is also shown.

#### Pretreatment and Post-Treatment Gray-Matter Changes in Hippocampal Cytoarchitectonic Subdivisions

The hippocampus is a complex structure including several subdivisions that are associated with different functions and pathologic conditions (25, 26). We explored whether such anatomic segregation enlightened interpretation of the correlations noted previously. Based on *a priori* hypotheses (10–14) we performed a small volume correction, region-of-interest analyses, and correlations with cognitive performance in the cytoarchitectonic subdivisions of the hippocampus (Table 4; additional details in Tables E2, E3, E5, and Figure E2) (23).

The results confirmed a significant GM-volume reduction in pretreatment OSA participants, compared with control subjects, in the right cornu ammonis and the entorhinal cortex bilaterally (Table E3). The amount of GM volume in the left entorhinal cortex was negatively correlated with errors in the

Stroop test (executive functions) (Table 4 and Table E2). After treatment, we observed a significant bilateral GM-volume increase in the cornu ammonis, entorhinal cortex, fascia dentata, and subiculum (Table E3), and GM increase in the left cornu ammonis correlated with improvement in the Stroop test (executive functions) (Table 4 and Table E2).

As for disease severity, AHI before treatment was negatively correlated with hippocampal GM volume in the bilateral cornu ammonis, entorhinal cortex, and fascia dentata ( $P < 0.05$ ). AHI before treatment was also positively correlated with hippocampal GM-volume increase after treatment in the bilateral cornu ammonis, entorhinal cortex, fascia dentata, and subiculum ( $P < 0.05$ ) (see Table E5 for a complete description of the observed correlations in the cytoarchitectonic subdivisions of the hippocampus) (23).

#### Reanalysis of the Data with the “Optimized-VBM”

Similarly to previous results (17), when we used the “optimized” VBM in SPM2 no regions survived a threshold of  $P$  less than 0.05 corrected for multiple comparisons, be it with false-discovery rate at the voxel level or family-wise error at the cluster level as in our analysis. At  $P$  less than 0.001 uncorrected we observed, in pretreatment patients compared with control subjects, scattered regions of GM-volume reduction and increase. At the same threshold, in post-treatment compared with pretreatment patients we found bilateral increases of GM volume in the left middle frontal gyrus and postcentral gyrus, and no region in the opposite comparison (Table E6).

#### DISCUSSION

The aims of this study were to investigate the neuropsychologic deficits in severe OSA and their association with structural brain changes, and to assess whether any cognitive improvement in patients with OSA after 3 months of CPAP treatment reflected a change in the underlying cerebral structure.

#### Cognitive and Structural Deficits at Baseline

Neuropsychologic results demonstrated impairments in memory, attention, executive functions and constructional abilities, as well as higher sleepiness and lower score in the Beck Depression Inventory (mood), in untreated patients with OSA. These impairments were associated with focal GM-volume reductions in the left hippocampal entorhinal cortex, in the left posterior parietal cortex, and in the right superior frontal gyrus.

Alterations in hippocampal structures have been previously reported in patients with OSA using VBM (10–12), quantitative magnetic resonance imaging (13), and spectroscopy (14). The location of the hippocampal cluster is consistent with previous results (10), and regions-of-interest analyses highlighted a significant GM-volume decrease in the same region (right cornu ammonis) where a GM-density reduction was previously reported (11). The hippocampus is extremely sensitive to hypoxic damage, and in rats exposed to intermittent hypoxia during sleep impaired spatial learning is associated with increased apoptosis within region CA1 (6). Gale and Hopkins (13) reported hippocampal atrophy associated with memory impairments both in patients with OSA and patients with carbon-monoxide poisoning. The hippocampal changes in OSA may also be associated with the attentional and executive impairment displayed by neuropsychologic tests, because the connections between the prefrontal cortex and the thalamus are extensive (27). The attentional, executive, and constructional deficits may also reflect the GM-volume decrease in superior parietal and frontal regions involved in attention (28) and working memory (29). Reduced cerebral activity in the right superior frontal gyrus has been reported in patients with OSA

TABLE 3. VOXEL-BASED MORPHOMETRY RESULTS

Hemisphere	Anatomic Region ( <i>Brodman-area/structure</i> )	K	Z Score
Controls > pretreatment			
Right	Superior frontal gyrus (6)	8625	4.43
Left	Inferior parietal lobule	5966	3.88
Left	Parahippocampal gyrus (entorhinal cortex*)	798	3.28 <sup>†</sup>
Post-treatment > pretreatment			
Left	Hippocampus (subiculum*)	3807	4.41
Left	Parahippocampal gyrus (entorhinal cortex*)	1600	3.89
Right	Hippocampus (entorhinal cortex)	1684	3.82
Right/Left	Midorbital gyrus (11/10)	1666	4.03
Right	Middle/superior frontal gyrus (46/10)	2333	3.99
Pretreatment and post-treatment (conjunction analysis)			
Left	Parahippocampal gyrus (entorhinal cortex*)	149	3.76 <sup>†</sup>

From top to bottom, cerebral regions showing a significant GM-volume change at baseline (controls > OSA pretreatment), at follow-up (OSA post-treatment > OSA pretreatment), and both at baseline and follow-up, in the main voxel-based morphometry analysis.  $P < 0.05$  corrected for multiple comparisons based on cluster-extent. K = cluster extent in number of voxels ( $1 \times 1 \times 1 \text{ mm}^3$ ) (see Table E1 for complete cytoarchitectonic labeling of the observed clusters with the SPM Anatomy-Toolbox) (22).

\* Probabilistic assignment by the Anatomy-Toolbox (22).

<sup>†</sup> Uncorrected threshold of  $P < 0.001$  based on *a priori* hypotheses (10–14).

compared with healthy control subjects when performing a specialized task to assess working memory (30, 31).

Overall, the significant correlation between the amount of localized GM-volume reduction (left posterior parietal cortex, right superior frontal gyrus, left entorhinal cortex, as well as the left entorhinal cortex hippocampal cytoarchitectonic subdivision) and performance on the Stroop test supports the hypothesis that executive dysfunction is a core component of the OSA neuropsychologic syndrome.

#### Cognitive and Structural Improvement after Treatment

After 3 months of treatment we observed a significant improvement in all cognitive domains. This improvement was related to a GM-volume increase in the hippocampus (left subiculum and

bilateral entorhinal cortex), the medial orbitofrontal cortex, and the rostral portion of the right superior frontal gyrus. When focusing on the cytoarchitectonic subdivision of the hippocampus (22, 23), a GM-volume increase was observed bilaterally in the cornu ammonis, entorhinal cortex, fascia dentata, and subiculum after treatment. These results are strengthened by the significant correlation between reduction of errors at the Stroop test and GM-volume increase in the left subiculum in the VBM analysis, and in the cornu ammonis in the region-of-interest analysis. In the case of the entorhinal cortex, the amount of GM increase after treatment was correlated with improvement in verbal and visuospatial short-term memory, attention and executive functioning, indicating a direct correlation between the GM changes and cognitive improvement.

TABLE 4. CORRELATION BETWEEN NEUROSTRUCTURAL AND COGNITIVE CHANGES IN THE VBM CLUSTERS AND HIPPOCAMPAL CYTOARCHITECTONIC SUBDIVISIONS

	Raven	Digit Forward	Corsi	Stroop-errors	ESS
Averaged GM Volume in VBM Clusters					
Pretreatment OSA: GM Volume and Performance					
Right superior frontal gyrus				−0.621	
	ns	ns	ns	0.01*	ns
Left posterior parietal cortex	0.604			−0.661	−0.610
	0.01*	ns	ns	0.005*	0.009*
Left hippocampus (entorhinal cortex)				−0.704	
	ns	ns	ns	0.002*	ns
Post-treatment OSA Patients: GM-volume Increase and Cognitive Improvement					
Left hippocampus (subiculum)				−0.725	
	ns	ns	ns	0.002*	ns
Pretreatment and Post-treatment OSA Patients (conjunction analysis): GM Volume and Performance Change					
Left hippocampus (entorhinal cortex)		0.726	0.554	−0.676	
	ns	0.001*	0.02*	0.005*	ns
Averaged GM Volume in Cytoarchitectonic Hippocampal ROIs from the Anatomy-Toolbox					
Pretreatment OSA: GM Volume and Performance					
Left entorhinal cortex				−0.802	
	ns	ns	ns	0.0001*	ns
Post-treatment OSA Patients: GM Volume Increase and Cognitive Improvement					
Left cornu ammonis				−0.736	
	ns	ns	ns	0.001*	ns

*Definition of abbreviations:* ESS = Epworth Sleepiness Scale; GM = gray matter; ns = nonstatistically significant; OSA = obstructive sleep apnea; ROIs = regions of interest; VBM = voxel-based morphometry.

Significant correlations between GM volume and scores at neurocognitive tests for the clusters resulting from the main VBM analysis (*top*) and the cytoarchitectonic subdivisions of the human hippocampus (22, 23) (*bottom*), before and after treatment. Within each cell, the number at the top indicates the value of the correlation, the one at the bottom (*in italic*) indicates the corresponding  $P$  value.

\* All reported correlations are significant at  $P < 0.05$  corrected for multiple comparisons with false-discovery rate (see Table E2 for the complete list of correlations significant at  $P < 0.05$  uncorrected for multiple comparisons).

**TABLE 5. CORRELATION BETWEEN DISEASE SEVERITY (AHI AND HYPOXIA) AND GM-VOLUME IN THE VBM CLUSTERS**

Brain region	AHI	Hypoxia (% time with Sa <sub>o<sub>2</sub></sub> <90%)
Pretreatment		
Right superior frontal gyrus	-0.46 <i>0.067</i>	-0.34 <i>0.188</i>
Left inferior parietal lobule	-0.69 <i>0.002*</i>	-0.58 <i>0.015*</i>
Left parahippocampal gyrus (enthorinal cortex)	-0.39 <i>0.123</i>	-0.39 <i>0.121</i>
Post-treatment		
Right/left mid orbital gyrus	0.41 <i>0.114</i>	0.26 <i>0.33</i>
Right middle/superior frontal gyrus	0.48 <i>0.061</i>	0.16 <i>0.55</i>
Right hippocampus (enthorinal cortex)	0.59 <i>0.015*</i>	0.57 <i>0.02*</i>
Left hippocampus (subiculum)	0.64 <i>0.007*</i>	0.51 <i>0.045*</i>
Left parahippocampal gyrus (enthorinal cortex)	0.49 <i>0.052</i>	0.45 <i>0.083</i>
Pretreatment and post-treatment		
Left parahippocampal gyrus (enthorinal cortex)	-0.39 <i>0.133</i>	-0.46 <i>0.072</i>

*Definition of abbreviations:* AHI = apnea-hypopnea index; GM = gray matter; VBM = voxel-based morphometry.

From top to bottom, correlations between disease severity (AHI and time with Sa<sub>o<sub>2</sub></sub> <90%) before treatment and GM volume before treatment, GM volume increase after treatment in the cerebral regions highlighted by the voxel-based morphometry analysis, and in the parahippocampal region where GM volume was both reduced before treatment and increased after treatment. Within each cell, the number at the left indicates the value of the correlation, the one at the right (*in italic*) indicates the corresponding *P* value.

\* Significant correlations (*P* < 0.05) (*see* Table E5 for a complete description of the observed correlations between GM volume and AHI in the cytoarchitectonic subdivisions of the hippocampus (23)).

Our results contradict the negative findings reported by O'Donoghue and coworkers (17) of no significant GM difference between pretreatment OSA and control subjects, and no changes after therapy. These findings conflict with those reported in other related VBM studies where significant GM reductions were shown in patients with OSA pretreatment (10–12). O'Donoghue and coworkers (17) interpreted their negative results in terms of different preprocessing of the data and different statistical analyses and threshold. However, it is crucial to take into consideration the continuous improvement of neuroimaging softwares, leading to more sensitive analyses and more robust results (16). Indeed, by using the same argument we demonstrated that the use of more recent VBM methods (VBM5-toolbox and SPM5-unified segmentation) compared with those previously used by O'Donoghue and coworkers (17) (the SPM2-optimized-VBM approach) enhanced sensitivity and specificity of our results (*see* online supplement).

The mechanisms leading to structural changes in VBM are a topic of intensive debate in light of the increasing literature on brain structural plasticity highlighted by morphometric analyses (16, 32). The human hippocampus retains its ability to generate neurons throughout life (33), and there is evidence that regular practice improves the rate of adult neurogenesis and fosters the preservation of newly generated neurons (34). Frontal and hippocampal structural plasticity caused by environmental enrichment has been shown in animal models (35).

These results may then suggest a scenario in which the hippocampus, because of its sensitivity to hypoxia and innervation of small vessels, is the region that is most strongly and quickly affected by hypoxic and hypercapnic episodes (6). The ensuing structural hippocampal damage results in cognitive deficits involving not only memory, but also attention and executive functioning, either directly (because of the role of hippocampus in these functions) (36) or indirectly (because of altered functional connectivity with the parietal and prefrontal cortex, which is also affected) (27). Yet, the hippocampal plasticity (35) allows for a structural recovery locally and in connected brain areas.

These results provide important clues in the debate over the pathogenesis of cognitive impairment in OSA and its reversibility. We propose a number of potential origins for the deficits demonstrated in our current findings. Both hypoxemia and sleep fragmentation have been proposed as potential contribu-

tors. The reversibility of structural changes has been suggested to indicate that they are secondary to sleep fragmentation, repetitive nocturnal hypoxemia, or disturbances in autonomic activity, rather than to preexisting cortical damage (17). To date, the lack of evidence for the reversibility of structural alterations in OSA has left this issue unresolved. Regardless of the origin of the deficit, the mechanism of brain change could be either neurogenic or vasogenic. We propose it to be vasogenic. We believe that the pattern of neuropsychologic changes in OSA is similar to that seen in cases with mild cerebrovascular disease (most commonly small vessel disease). The microvascular model of OSA has been posited previously and supported in some studies. Moreover, this model lends itself nicely to further evaluation using more sophisticated methods to assess microbleeds and other small vessel abnormalities in the brain. Finally, this explanation is parsimonious with many of the positive cardiovascular studies in OSA. The true origin and mechanism, however, are yet to be uncovered.

There are many potential implications for the results presented herein. If the cause of impairment is vasogenic, there are treatment approaches (e.g., steroid therapy) that could mediate the long-term effects of vasogenic edema in the brain. Whatever the cause, identifying the underlying mechanism could open doors for treatment approaches to avoid the brain-related changes demonstrated through our study. The association between the VBM findings and severity of disease may also be important. Such findings, if replicated, can serve as a marker of long-term negative outcomes associated with OSA. This could initiate more intensive follow-up or additional testing to identify early indicators of brain involvement (e.g., neuroimaging or neuropsychologic testing). Finally, these data could serve as motivators for patients to be adherent to treatment. If such findings are shared with patients, risk perception of nonadherence could be increased, thus increasing adherence to treatment. It should be noted, however, that these findings must first be replicated and taken to more depth regarding their causative factors. A limitation of our study is that healthy control subjects were not reevaluated at 3 months, a restriction caused by practical considerations of study cost and participant availability for repeated scanning. In principle, the absence of this control would not allow one to exclude either an effect of learning on cognitive performance or of "spontaneous" brain changes.

However, several considerations speak against this interpretation. Our neuropsychologic battery included tests that are unlikely to be prone to significant learning effects, except for the Rey list learning, for which an alternate yet equivalent form was used at the 3-month assessment. As for the post-treatment neural changes observed in patients, none of the regions showing a GM-volume increase in the present study has been associated with an age-related enlargement. Global GM volume linearly decreases with age (15), and age-related loss of GM concentration has been reported in several regions (15) including the hippocampus (37). Finally, the significant correlation between cognitive improvement in specific tests and the GM-volume increase in specific regions strengthens our conclusions. No spontaneous improvement in test performance has been reported with sham treatment (38). Additionally, it is worth highlighting that our sample included severe hypoxic patients (percent of time spent with  $\text{SaO}_2 < 90\% = 30.4 \pm 13.4$ ). A study with nonhypoxic sleepy patients is warranted.

In summary, this study provides the first evidence that structural brain abnormalities exist in regions susceptible to hypoxemia, and that they can change with treatment. These results suggest that even the negative neurologic effects of hypoxemia may reverse with consistent and thorough treatment. Therefore, adherence to treatment can lead not only to clinical, but also to brain-structural recovery. It must be underlined that the patients in this trial showed a positive response to treatment. The magnetic resonance imaging changes may thus represent a marker of treatment response.

**Author Disclosure:** N.C. does not have a financial relationship with a commercial entity that has an interest in the subject of this manuscript. V.C. received \$10,001–\$50,000 from Respiroics in consultancy fees. S.F.C. received \$1,001–\$5,000 from Novartis in lecture fees, up to \$1,000 from Oxford University Press, and up to \$1,000 from Imperial College Press in royalties. M.S.A. is a full-time employee of Philips/Respiroics, Inc., and holds \$10,001–\$50,000 in employee stock benefit from Philips. S.M. does not have a financial relationship with a commercial entity that has an interest in the subject of this manuscript. A.F. does not have a financial relationship with a commercial entity that has an interest in the subject of this manuscript. L.F.S. received \$5,001–\$10,000 from UCB-Pharma, \$1,001–\$5,000 from GlaxoSmithKline, \$1,001–\$5,000 from Sanofi-Aventis, and \$5,001–\$10,000 from Boehringer Ingelheim in advisory board fees.

**Acknowledgment:** The authors acknowledge the help of Miss Antonella Iadanza, M.Sc. (Neuroradiology Unit, San Raffaele Scientific Institute, Milan, Italy) for technical support, and Mr. Daniele Bizzozero, M.Sc., Mr. Antonio Massimo, M.Sc., and Miss Cristina Martinelli, M.Sc. (Sleep Disorders Center, San Raffaele Scientific Institute, Milan, Italy) for polysomnographic recordings.

## References

- Young T, Peppard PE, Gottlieb DJ. Epidemiology of obstructive sleep apnea: a population health perspective. *Am J Respir Crit Care Med* 2002;165:1217–1239.
- Brown WD. The psychosocial aspects of obstructive sleep apnea. *Semin Respir Crit Care Med* 2005;26:33–43.
- Teran-Santos J, Jimenez-Gomez A, Cordero-Guevara J. The association between sleep apnea and the risk of traffic accidents. Cooperative Group Burgos-Santander. *N Engl J Med* 1999;340:847–851.
- Aloia MS, Arnedt JT, Davis JD, Riggs RL, Byrd D. Neuropsychological sequelae of obstructive sleep apnea-hypopnea syndrome: a critical review. *J Int Neuropsychol Soc* 2004;10:772–785.
- Ferini-Strambi L, Baietto C, Di Gioia MR, Castaldi P, Castronovo C, Zucconi M, Cappa SF. Cognitive dysfunction in patients with obstructive sleep apnea (OSA): partial reversibility after continuous positive airway pressure (CPAP). *Brain Res Bull* 2003;61:87–92.
- Gozal E, Row BW, Schurr A, Gozal D. Developmental differences in cortical and hippocampal vulnerability to intermittent hypoxia in the rat. *Neurosci Lett* 2001;305:197–201.
- Zimmerman ME, Aloia MS. A review of neuroimaging in obstructive sleep apnea. *J Clin Sleep Med* 2006;2:461–471.
- Ayalon L, Peterson S. Functional central nervous system imaging in the investigation of obstructive sleep apnea. *Curr Opin Pulm Med* 2007;13:479–483.
- Lanfranchi P, Somers VK. Obstructive sleep apnea and vascular disease. *Respir Res* 2001;2:315–319.
- Macey PM, Henderson LA, Macey KE, Alger JR, Frysinger RC, Woo MA, Harper RK, Yan-Go FL, Harper RM. Brain morphology associated with obstructive sleep apnea. *Am J Respir Crit Care Med* 2002;166:1382–1387.
- Morrell MJ, McRobbie DW, Quest RA, Cummin AR, Ghiassi R, Corfield DR. Changes in brain morphology associated with obstructive sleep apnea. *Sleep Med* 2003;4:451–454.
- Yaouhi K, Bertran F, Clochon P, Mézenge F, Denise P, Foret J, Eustache F, Desgranges B. A combined neuropsychological and brain imaging study of obstructive sleep apnea. *J Sleep Res* 2009;18:36–48.
- Gale SD, Hopkins RO. Effects of hypoxia on the brain: neuroimaging and neuropsychological findings following carbon monoxide poisoning and obstructive sleep apnea. *J Int Neuropsychol Soc* 2004;10:60–71.
- Bartlett DJ, Rae C, Thompson CH, Byth K, Joffe DA, Enright T, Grunstein RR. Hippocampal area metabolites relate to severity and cognitive function in obstructive sleep apnea. *Sleep Med* 2004;5:593–596.
- Good CD, Johnsrude IS, Ashburner J, Henson RN, Friston KJ, Frackowiak RS. A voxel-based morphometric study of ageing in 465 normal adult human brains. *Neuroimage* 2001;14:21–36.
- May A, Gaser C. Magnetic resonance-based morphometry: a window into structural plasticity of the brain. *Curr Opin Neurol* 2006;19:407–411.
- O'Donoghue FJ, Briellmann RS, Rochford PD, Abbott DF, Pell GS, Chan CH, Tarquinio N, Jackson GD, Pierce RJ. Cerebral structural changes in severe obstructive sleep apnea. *Am J Respir Crit Care Med* 2005;171:1185–1190.
- Ferini Strambi L, Canessa N, Castronovo V, Alemanno F, Aloia MS, Marelli S, Falini A, Cappa S. Brain structural changes in OSA patients before and after treatment. *Abstract Supplement* 2010;33:329, A116.
- Redline S, Budhiraja R, Kapur V, Marcus CL, Mateika JH, Mehra R, Parthasarathy S, Somers VK, Strohl KP, Sullit LG, et al. The scoring of respiratory events in sleep: reliability and validity. *J Clin Sleep Med* 2007;15:169–200.
- Lezak MD, Lezak MD. Neuropsychological assessment, 4th ed. Oxford: Oxford University Press; 2004.
- Hayasaka S, Phan KL, Liberzon I, Worsley KJ, Nichols TE. Non-stationary cluster-size inference with random field and permutation methods. *Neuroimage* 2004;22:676–687.
- Eickhoff SB, Stephan KE, Mohlberg H, Grefkes C, Fink GR, Amunts K, Zilles K. A new SPM toolbox for combining probabilistic cytoarchitectonic maps and functional imaging data. *Neuroimage* 2005;25:1325–1335.
- Amunts K, Kedo O, Kindler M, Pieperhoff P, Mohlberg H, Shah NJ, Habel U, Schneider F, Zilles K. Cytoarchitectonic mapping of the human amygdala, hippocampal region and entorhinal cortex: inter-subject variability and probability maps. *Anat Embryol (Berl)* 2005;210:343–352. (Berl).
- Nichols T, Brett M, Andersson J, Wager T, Poline JB. Valid conjunction inference with the minimum statistic. *Neuroimage* 2005;25:653–660.
- Narr KL, Thompson PM, Szeszko P, Robinson D, Jang S, Woods RP, Kim S, Hayashi KM, Asuncion D, Toga AW, et al. Regional specificity of hippocampal volume reductions in first-episode schizophrenia. *Neuroimage* 2004;21:1563–1575.
- Schacter DL, Wagner AD. Medial temporal lobe activations in fMRI and PET studies of episodic encoding and retrieval. *Hippocampus* 1999;9:7–24.
- Newberg AB, Iversen J. The neural basis of the complex mental task of meditation: neurotransmitter and neurochemical considerations. *Med Hypotheses* 2003;61:282–291.
- Sturm W, Willmes K. On the functional neuroanatomy of intrinsic and phasic alertness. *Neuroimage* 2001;14:S76–S84.
- Owen AM, McMillan KM, Laird AR, Bullmore E. N-back working memory paradigm: a meta-analysis of normative functional neuroimaging studies. *Hum Brain Mapp* 2005;25:46–59.
- Thomas RJ, Rosen BR, Stern CE, Weiss JW, Kwong KK. Functional imaging of working memory in obstructive sleep-disordered breathing. *J Appl Physiol* 2005;98:2226–2234.
- Castronovo V, Canessa N, Strambi LF, Aloia MS, Consonni M, Marelli S, Iadanza A, Bruschi A, Falini A, Cappa SF. Brain activation changes before and after PAP treatment in obstructive sleep apnea. *Sleep* 2009;32:1161–1172.
- Mietchen D, Gaser C. Computational morphometry for detecting changes in brain structure due to development, aging, learning, disease and evolution. *Front Neuroinformatics* 2009;3:25.

33. Eriksson PS, Perfilieva E, Björk-Eriksson T, Alborn AM, Nordborg C, Peterson DA, Gage FH. Neurogenesis in the adult human hippocampus. *Nat Med* 1998;4:1313–1317.
34. Gage FH. Neurogenesis in the adult brain. *J Neurosci* 2002;22:612–613.
35. Kempermann G, Gast D, Gage FH. Neuroplasticity in old age: sustained fivefold induction of hippocampal neurogenesis by long-term environmental enrichment. *Ann Neurol* 2002;52:135–143.
36. Bondi MW, Serody AB, Chan AS, Ebersson-Shumate SC, Delis DC, Hansen LA, Salmon DP. Cognitive and neuropathologic correlates of Stroop Color-Word Test performance in Alzheimer's disease. *Neuropsychology* 2002;16:335–343.
37. Pruessner JC, Collins DL, Pruessner M, Evans AC. Age and gender predict volume decline in the anterior and posterior hippocampus in early adulthood. *J Neurosci* 2001;21:194–200.
38. Lim W, Bardwell WA, Lored JS, Kim EJ, Ancoli-Israel S, Morgan EE, Heaton RK, Dimsdale JE. Neuropsychological effects of 2-week continuous positive airway pressure treatment and supplemental oxygen in patients with obstructive sleep apnea: a randomized placebo-controlled study. *J Clin Sleep Med* 2007;3:380–386.